

# Placement of Mini-Implants with Topical Anesthetic

NEAL D. KRAVITZ, DMD  
BUDI KUSNOTO, DDS, MS

**D**espite the benefits of skeletal anchorage,<sup>1-7</sup> many orthodontists have been reluctant to place miniscrews because of the need to administer local anesthetic injections. This article shows how mini-implants can be placed successfully and comfortably using only topical anesthetic.

## Mini-Implant Designs

With a “non-self-tapping” (or “pretapped”) screw, a pilot hole must be drilled, and a surgical tap is then used to create threads in the bone.<sup>8</sup> A “self-tapping” screw has a threaded body and a tapered furrow at the tip that cuts a thread into the bone, eliminating the need for a surgical tap. Self-tapping screws often require pilot drilling, particularly in areas of dense cortical bone or coarse trabecular bone,<sup>3,5,8,9</sup> but they generally save time compared to non-self-tapping screws.<sup>10</sup>

A “self-drilling” screw resembles a corkscrew, with a sharp tip and a threaded body.<sup>8</sup> The self-drilling screw works like a cutting flute, expelling bone debris onto the surface, without pilot drilling. Many orthodontic mini-implants are self-tapping, but not self-drilling. The procedure described here uses the self-tapping, self-drilling Dual-Top Anchor System,\* which requires only a screwdriver for placement, optimizing tactile control and greatly simplifying the insertion procedure.<sup>1,11</sup>

## Mini-Implant Insertion with Topical Anesthetic

A 2" × 2" gauze pad is used to thoroughly dry the mucosal area where the miniscrew is to be implanted. The recommended dosage of a topical anesthetic gel is applied to the dry mucosa with a cotton swab (Fig. 1), and the gel is left in place for two to three minutes.<sup>12</sup> Longer exposure may cause tissue irritation. Peak anesthesia is usually reached in five to 10 minutes and lasts 25-30 minutes.<sup>12</sup>

A periodontic probe is used to confirm pro-

found anesthesia. The probe also creates a precise soft-tissue marker to guide the mini-implant after radiographic verification.<sup>5</sup>

The miniscrew is inserted at an angle of 45° to the occlusal plane, using slow, intermittent turns of the screwdriver. This method allows a comfortable underhand grip, with the elbow stabilized and only the thumb and index finger needed to rotate the screwdriver (Fig. 2).

Figure 3 shows a patient in which the edentulous region just distal to the mandibular left canine was selected for miniscrew placement because of the minimal risk of root perforation. Placing the mini-implant in the attached gingiva avoids tissue bunching and overgrowth. A topical anesthetic gel was applied as described above, and the patient reported no discomfort during the placement procedure. Thirty minutes later, she noted that normal cheek sensation was beginning to return.

After insertion, the patient was prescribed 20ml of chlorhexidine rinse to be used three times a day, and was instructed to keep the miniscrew covered with wax 24 hours a day for seven days to minimize tissue overgrowth and aphthous ulceration.<sup>1,9,13</sup> Patients who have difficulty keeping the wax on the mini-implant head, such as elderly patients with impaired manual dexterity, may use a slightly moist cotton ball as an alternative. One week after insertion, this patient displayed good gingival health around the mini-implant and reported little to no discomfort following the procedure.

Figure 4 shows a case requiring bilateral miniscrews in the mandibular first molar regions for molar intrusion. The right mini-implant was placed under local anesthesia, the left with a topical anesthetic gel as described above. The patient reported no discomfort during the procedure, and

\*Jeil Medical Corporation, #702, Kolon Science Valley II, 822, Guro-ku, Guro-dong, Seoul 152-050, Korea; www.jeilmed.co.kr. Distributed by Rocky Mountain Orthodontics, Inc., 650 W. Colfax Ave., Denver, CO 80204; www.rmortho.com.

Dr. Kravitz is a resident and Dr. Kusnoto is Clinical Chair, Department of Orthodontics, College of Dentistry, University of Illinois, MC 841, Chicago, IL 60612. E-mail Dr. Kravitz at neal\_kravitz@yahoo.com.



Dr. Kravitz



Dr. Kusnoto

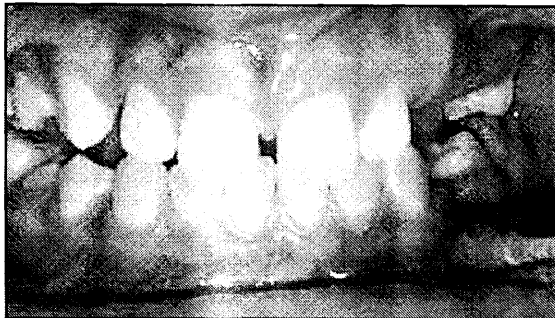


Fig. 1 Application of topical anesthetic gel.

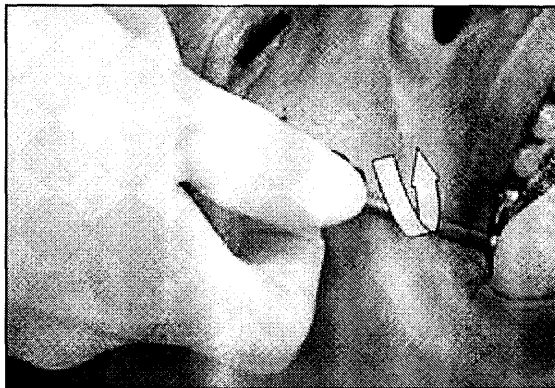


Fig. 2 Miniscrew insertion with screwdriver and light pressure.

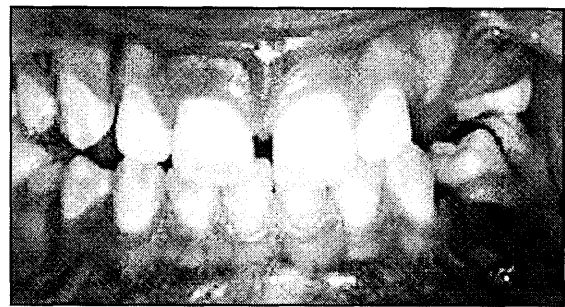


Fig. 3 Miniscrew placed in edentulous region distal to mandibular left canine.

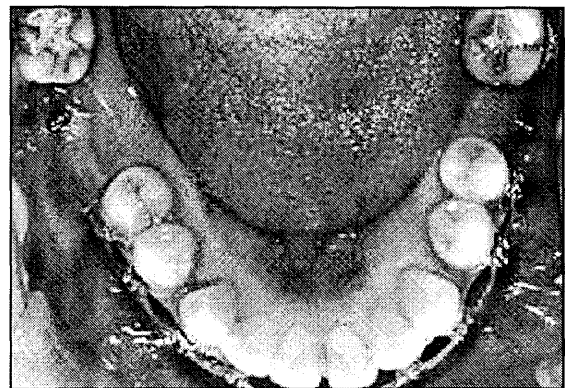


Fig. 4 Patient with right posterior miniscrew implanted under local anesthesia and left miniscrew under topical anesthesia.

actually preferred the flavor of the topical anesthetic. Thirty minutes later, the patient did relate mild discomfort on both sides, along with a return of normal cheek sensation.

After-care was prescribed as in the first case. One week after insertion, the patient displayed good gingival health around both mini-implants. She reported that her mild discomfort had subsided by the evening of the placement procedure.

## Discussion

Any type of mini-implant has inherent risks.

With both self-tapping and self-drilling screws, the greatest risk is that of damage to adjacent structures such as dental roots, blood vessels, and nerves.<sup>1,5,13</sup> In addition, when a pilot hole is created, there is a possibility that the drill bit may break, or that thermal damage to the bone may lead to infection and osteomyelitis.<sup>8,11</sup> If a pilot hole is not drilled, there is a chance that the screw may slip during insertion in an area of thick cortical bone, or that the implant may fail if placed in thin cortical bone.<sup>8</sup>

Self-drilling mini-implants eliminate the need for a slow-speed purchase point and pilot drilling, except in areas that require steep angles of inser-

## Placement of Mini-Implants with Topical Anesthetic

tion. In the maxillary arch, the angle of insertion should be 40-90° to the occlusal plane; an oblique angle reduces the risk of root perforation.<sup>3</sup> Maxillary mini-implants placed perpendicular to the occlusal floor beneath the paranasal sinuses can be inserted at a steeper angle, but should be reserved for edentulous regions or cases where maximum intrusive forces are needed. In the mandibular arch, a 30-45° angle of insertion will maximize the surface area of the cortical bone.<sup>3</sup> A steeper angulation may require a purchase point to prevent the miniscrew from sliding down the buccal shelf under the mucosa.

Regardless of the angle of insertion, minimal pressure should be used for miniscrew placement. Increased pressure may be a sign that the mini-implant is sliding against the cortical surface, rather than engaging into the bone—which can be particularly dangerous in the retromolar and zygomatic regions.

Topical anesthetics offer a number of advantages when used for mini-implant insertion.<sup>12,14,15</sup> First, the anesthetic gel is easily administered by the clinician and comfortably tolerated by the patient. Second, there is no pulpal anesthesia, because topical anesthetics effectively diffuse through only 2-3mm of mucous membranes, while tissues deeper than 3mm are poorly anesthetized.<sup>16</sup> Third, tissue ballooning does not occur, as it can after local infiltration.

Topical anesthetics may be contraindicated in elderly patients, patients with hypersensitivity to ester-type and amide-type local anesthetics, patients with para-aminobenzoic acid allergies, and patients with severe hypertension, ventricular tachycardia, hyperthyroidism, bradycardia, partial heart block, myocardial disease, or severe arteriosclerosis.<sup>16</sup>

ACKNOWLEDGMENT: The authors would like to thank Dr. Thomas Graber for his editorial guidance and expertise.

### REFERENCES

1. Suarez, D.: Miniscrews and the orthodontist: Should they be used? *Convention News, Rocky Mountain Orthodontics*, May 2005, pp. 12-21.
2. Roberts, W.E.; Smith, R.K.; Silberman, Y.; Mozsary, P.G.; and Smith, R.S.: Osseous adaptation to continuous loading of rigid endosseous implants, *Am. J. Orthod.* 86:95-111, 1984.
3. Carano, A.; Velo, S.; Leone, P.; and Siciliani, G.: Clinical applications of the Miniscrew Anchorage System, *J. Clin. Orthod.* 39:9-24, 2005.
4. Kuroda, S.; Sugawara, Y.; Yamashita, K.; Mano, T.; and Takano-Yamamoto, T.: Skeletal Class III oligodontia patient treated with titanium screw anchorage and orthognathic surgery, *Am. J. Orthod.* 127:730-738, 2005.
5. Lin, J.C.Y. and Liou, E.J.W.: A new bone screw for orthodontic anchorage, *J. Clin. Orthod.* 37:676-681, 2003.
6. Huang, L.H.; Shotwell, J.L.; and Wang, H.L.: Dental implants for orthodontic anchorage, *Am. J. Orthod.* 127:713-722, 2005.
7. Cousley, R.: Critical aspects in the use of orthodontic palatal implants, *Am. J. Orthod.* 127:723-729, 2005.
8. Sowden, D. and Schmitz, J.P.: AO self-drilling and self-tapping screws in rat calvarial bone: An ultrastructural study of the implant interface, *J. Oral Maxillofac. Surg.* 60:294-299, 2002.
9. Liou, E.J.; Pai, B.C.; and Lin, J.C.: Do miniscrews remain stationary under orthodontic forces? *Am. J. Orthod.* 126:42-47, 2004.
10. Baumgart, F.W.; Cordey, J.; Morikawa, K.; Perren, S.M.; Rohn, B.A.; Schavan, R.; and Snyder, S.: AO/ASIF self-tapping screws (STS). *Injury* 24(suppl. 1):S1-S17, 1993.
11. Heidemann, W.; Gerlach, K.; Grobel, K.H.; and Kollner, H.G.: Drill free screws: A new form of osteosynthesis screw, *J. Craniomaxillofac. Surg.* 26:163-168, 1998.
12. Zempsky, W.T. and Karasic, R.B.: EMLA versus TAC for topical anesthesia of extremity wounds in children, *Ann. Emerg. Med.* 30:163-166, 1997.
13. Maino, B.G.; Bednar, J.; Pagin, P.; and Mura, P.: The Spider Screw for skeletal anchorage, *J. Clin. Orthod.* 37:90-97, 2003.
14. Kundu, S. and Achar, S.: Principles of office anesthesia, Part II: Topical anesthesia, *Am. Fam. Phys.* 66:99-102, 2002.
15. Keyes, P.D.; Tallon, J.M.; and Rizos, J.: Topical anesthesia, *Can. Fam. Phys.* 44:2152-2156, 1998.
16. Malamed, S.F.: *Handbook of Local Anesthesia*, 4th ed., Mosby, St. Louis, 1997.